



C SCANS

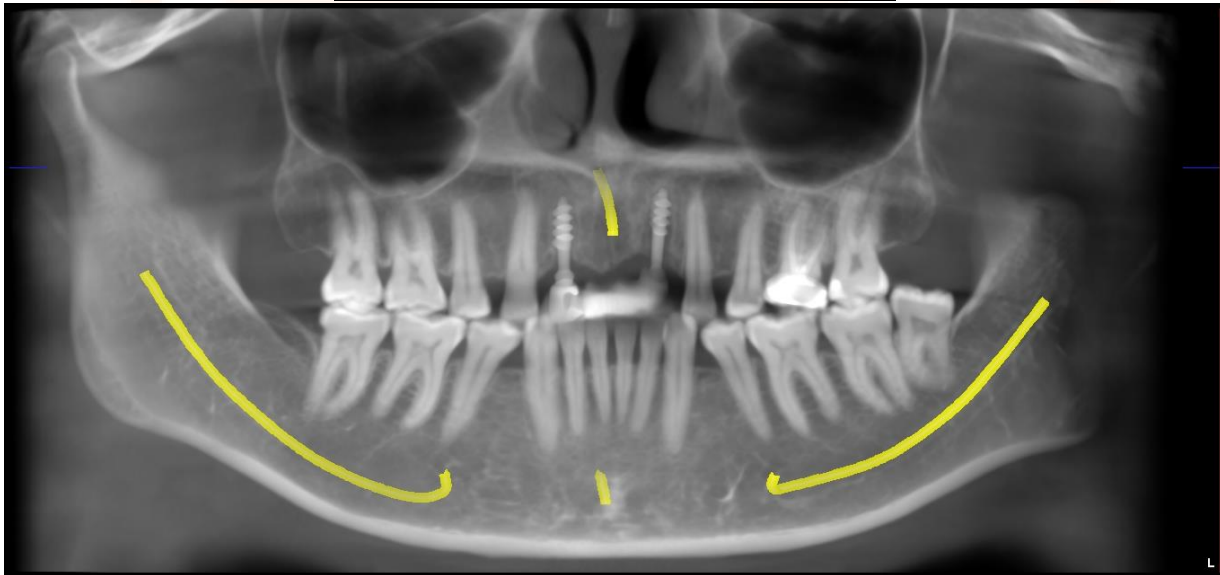
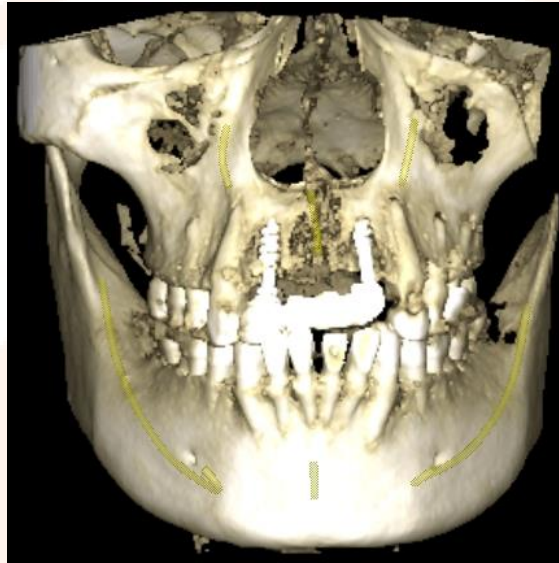2D & 3D Digital Imaging
state of the art CBCT scan centre

CBCT REPORT



Date: 03/06/2023

Patient's Name	Mrs. Monisha
Patient's Age/Gender	35/F
FOV and parameters	10x10cm, 150 – micron resolution
Remarks	Region – Maxilla and Mandible



Rendered and panoramic images of the region

Teeth seen in the volume:

	17	16	15		13				23		25	26	27	
	47	46	45		43	42	41	31	32	33	35	36	37	38

C Scans

1

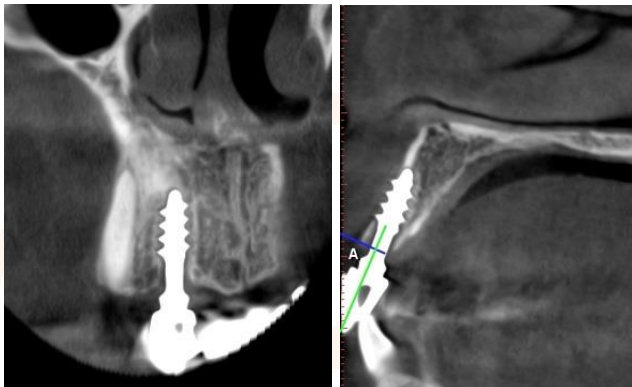


RADIOGRAPHIC EXAMINATION

Teeth seen in the volume:

Region of 12:

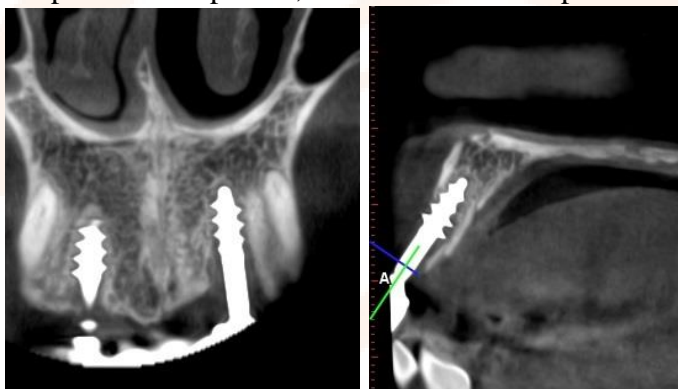
Basal implant noted in the region of 12 measuring 2x13.5mm in dimensions. The implant is noted engaging the labial cortex.



12- Coronal and Sagittal sections

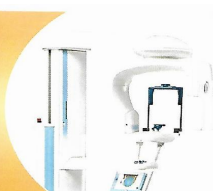Region of 22:

Basal implant noted in the region of 22 measuring 2x16mm in dimensions. There is no labial cortex noted along the coronal half of labial surface of the implant. Alveolar bone loss noted till the middle third of the implant on the palatal, mesial and distal aspects.



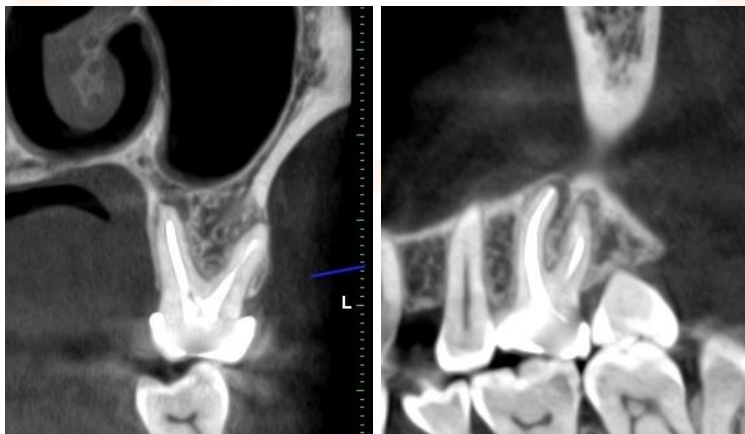
22- Coronal and Sagittal sections

Tooth Number	Crown	Root	Periapical Region & Periodontium
17	No abnormality detected	3 roots and 3 canals	No abnormality detected
16	No abnormality detected	3 roots and 3 canals	No abnormality detected
15	No abnormality detected	1 root and 1 canal	No abnormality detected
13	No abnormality detected	1 root and 1 canal	No abnormality detected
23	No abnormality detected	1 root and 1 canal	No abnormality detected
25	No abnormality detected	1 root and 1 canal	No abnormality detected
26	Well-defined radiopacity noted around the coronal structure, suggestive of a crown.	3 roots and 3 canals The mesiobuccal root canal appears restored with radiopaque material till the root apex. The	Well-defined radiolucencies noted around the apices of mesiobuccal and palatal roots.



		palatal and distobuccal canals appear restored with radiopaque material 1mm short of the apices.	
27	Well-defined radiopacity noted on the mesial surface of crown involving the enamel and dentin, suggestive of a restoration.	3 roots and 3 canals	No abnormality detected
38	No abnormality detected	2 roots and 2 canals	No abnormality detected
37	No abnormality detected	2 roots and 2 canals	No abnormality detected
36	Diffuse radiolucency noted on the distal surface of crown involving the enamel and dentin.	2 roots and 3 canals	No abnormality detected
35	No abnormality detected	1 root and 1 canal	No abnormality detected
33	No abnormality detected	1 root and 1 canal	No abnormality detected
32	No abnormality detected	1 root and 1 canal	No abnormality detected
31	No abnormality detected	1 root and 1 canal	No abnormality detected
41	No abnormality detected	1 root and 1 canal	No abnormality detected
42	No abnormality detected	1 root and 1 canal	No abnormality detected
43	No abnormality detected	1 root and 1 canal	No abnormality detected
45	No abnormality detected	1 root and 1 canal	No abnormality detected
46	No abnormality detected	2 roots and 3 canals	No abnormality detected
47	Diffuse radiolucency noted on the distal surface of crown involving the enamel and dentin.	2 roots and 2 canals	No abnormality detected

Maxillary sinus: The right and left maxillary sinuses appear normal.



26- Coronal section of palatal and distobuccal roots; Sagittal section of mesiobuccal root



C SCANS

2D & 3D Digital Imaging

state of the art CBCT scan centre



CBCT REPORT

RADIOGRAPHIC IMPRESSION:

1. Periapical granuloma irt 26
2. Dental caries irt 36, 47

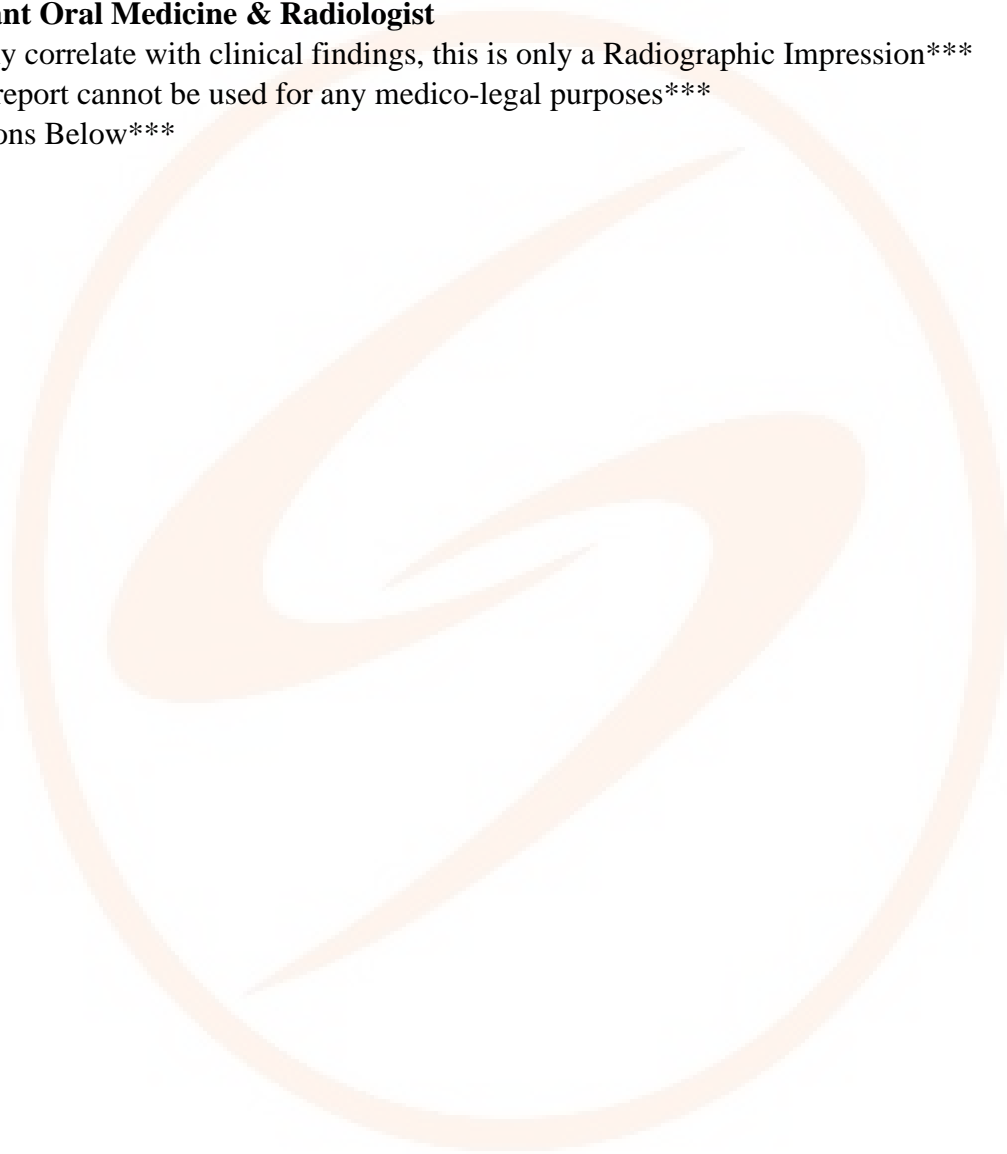
Dr. Vinitra Vasan, MDS

Consultant Oral Medicine & Radiologist

Kindly correlate with clinical findings, this is only a Radiographic Impression

This report cannot be used for any medico-legal purposes

Sections Below



C Scans



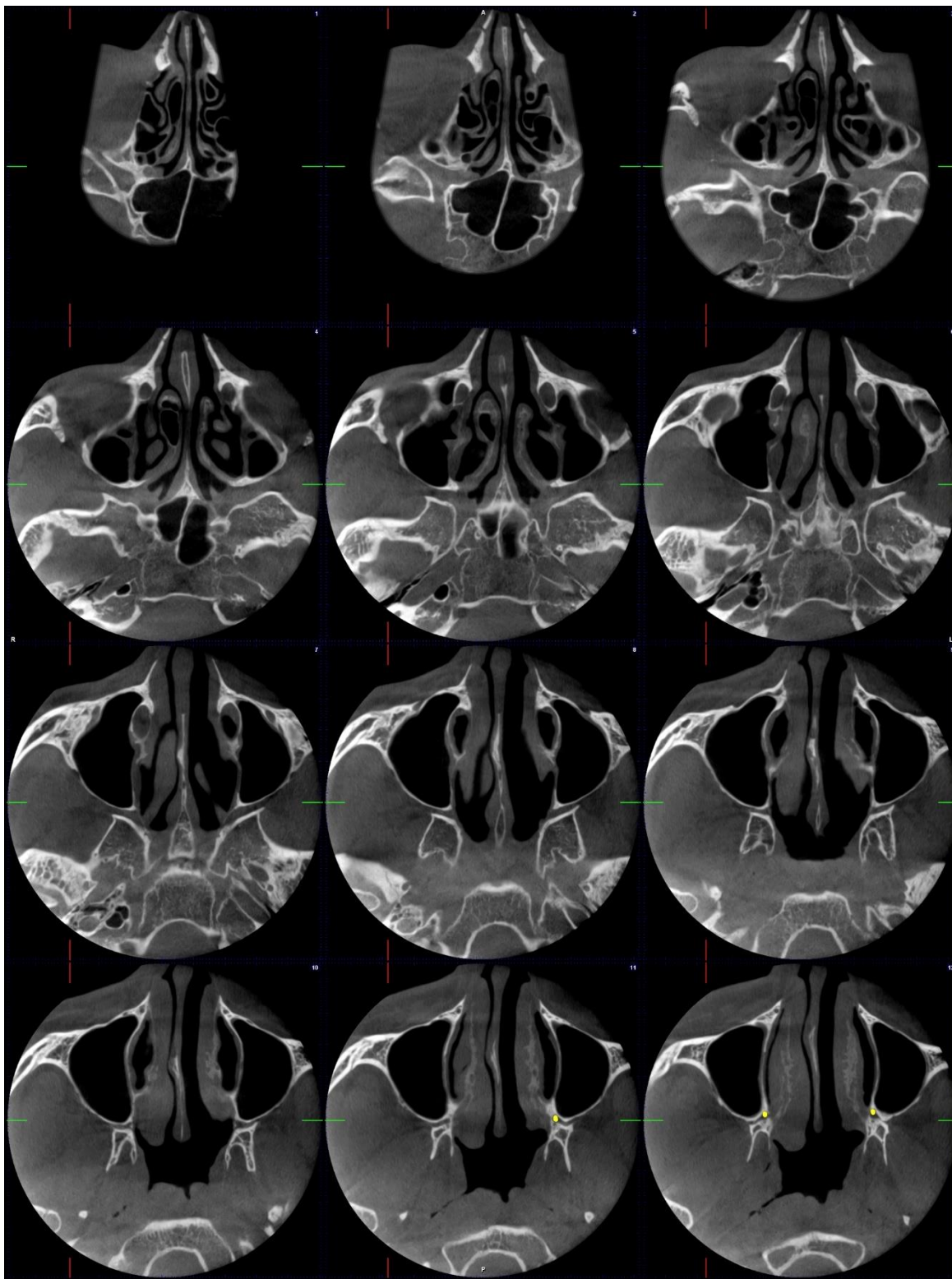
C SCANS

2D & 3D Digital Imaging
state of the art CBCT scan centre



CBCT REPORT

Axial 2mm sections (Coronal to cervical)

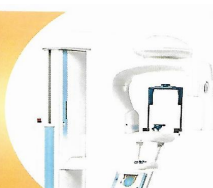

C Scans

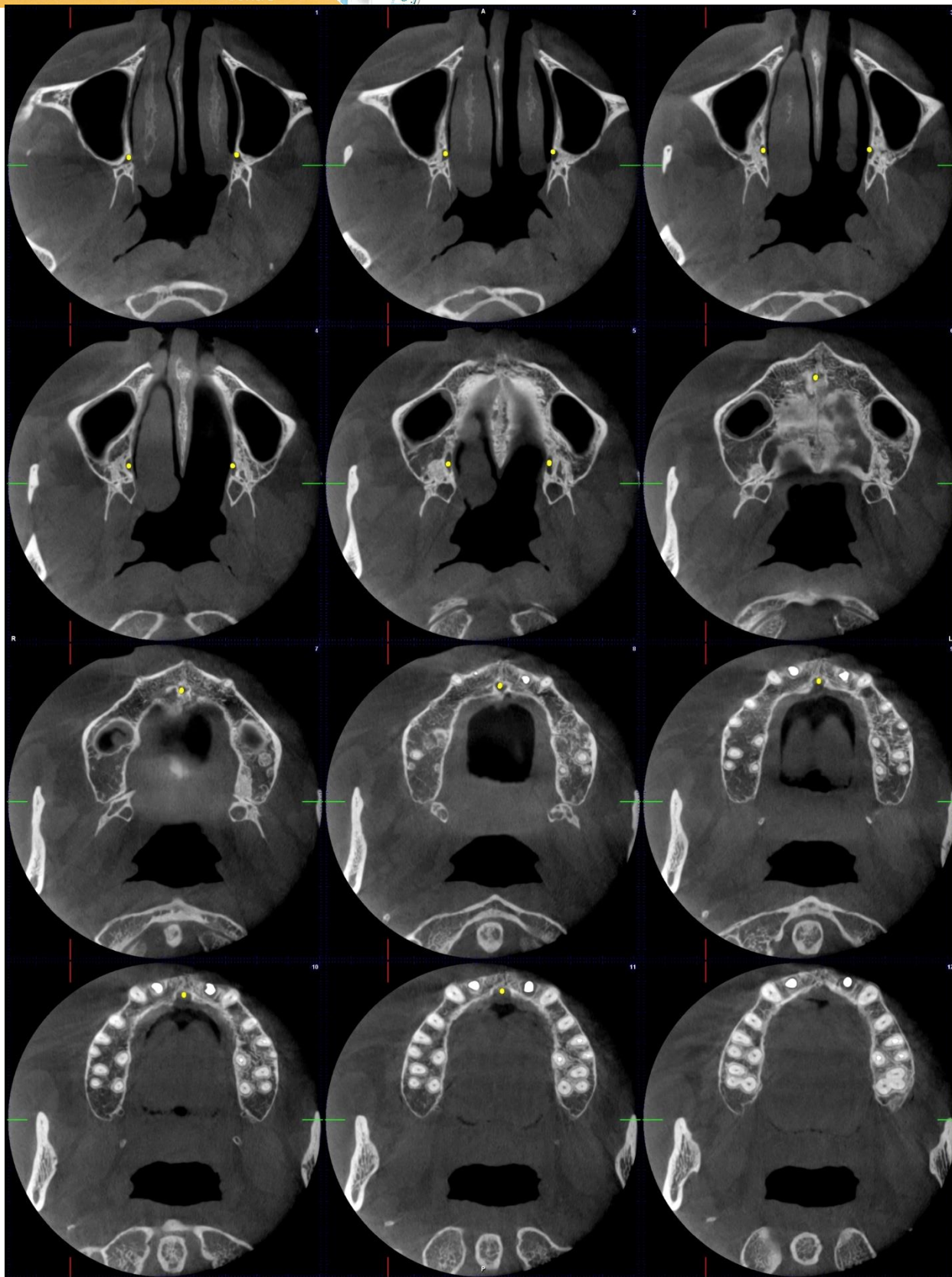


C SCANS

2D & 3D Digital Imaging
state of the art CBCT scan centre



CBCT REPORT



C Scans

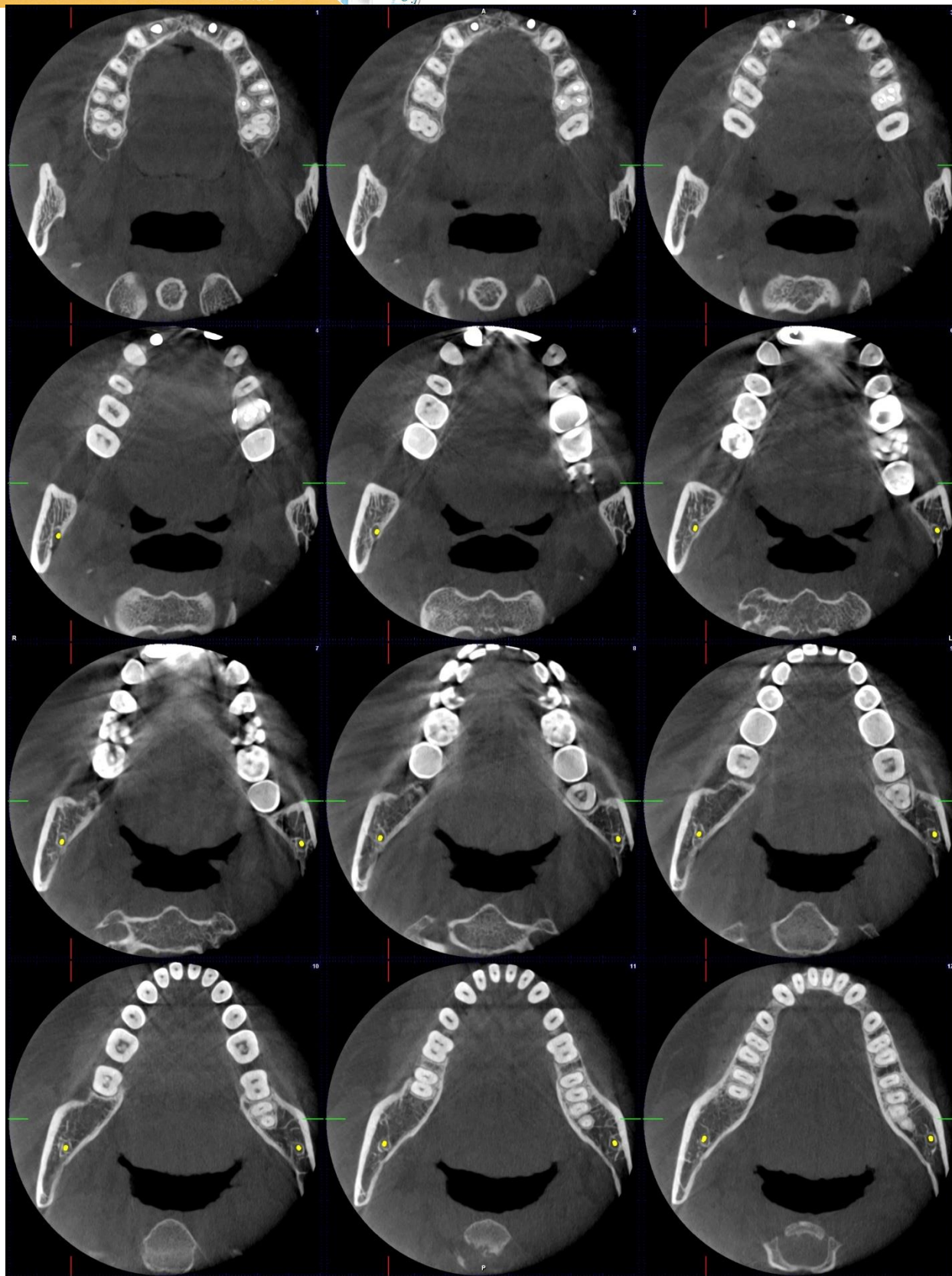


C SCANS

2D & 3D Digital Imaging
state of the art CBCT scan centre



CBCT REPORT



C Scans

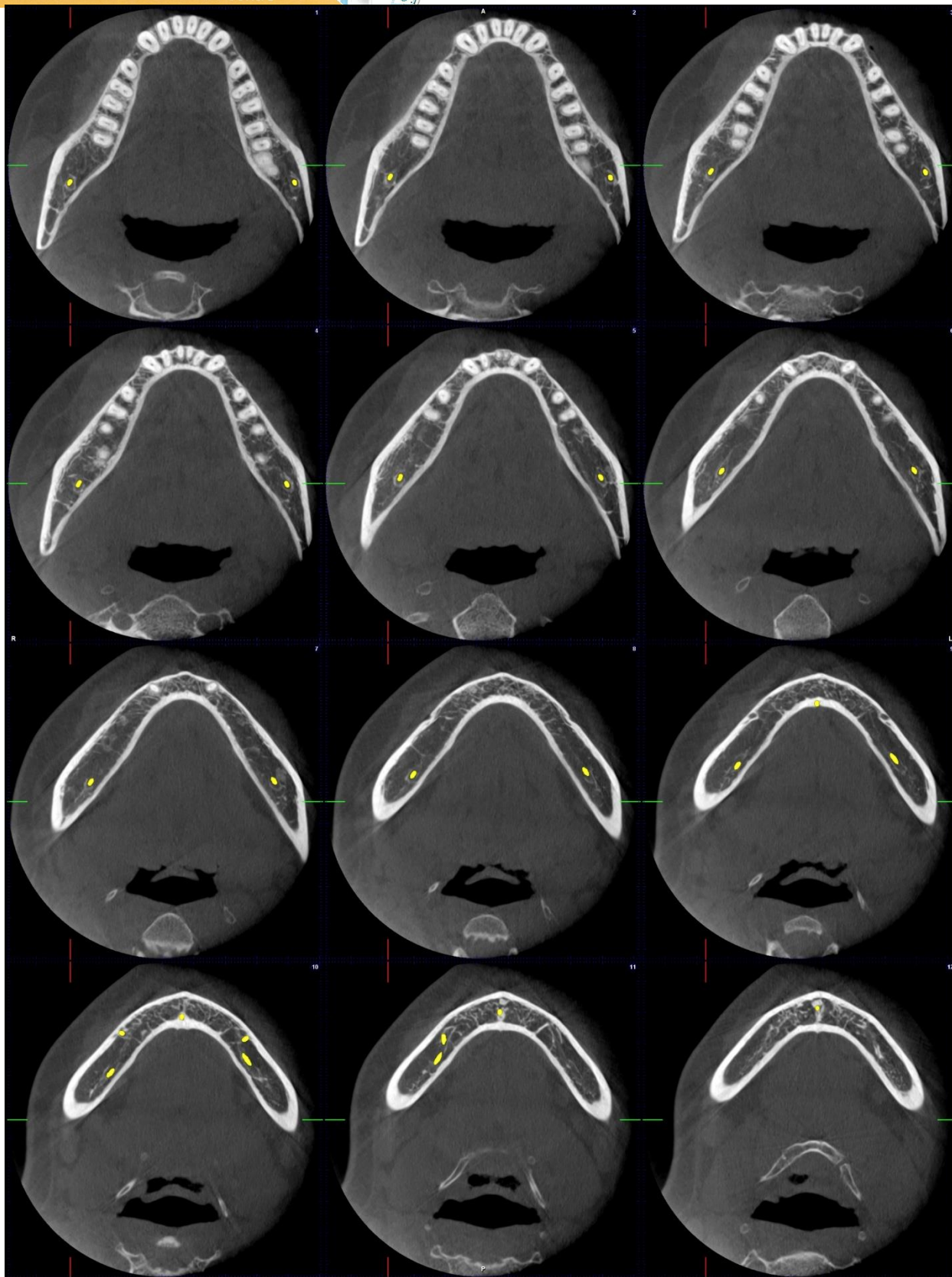


C SCANS

2D & 3D Digital Imaging
state of the art CBCT scan centre



CBCT REPORT



C Scans



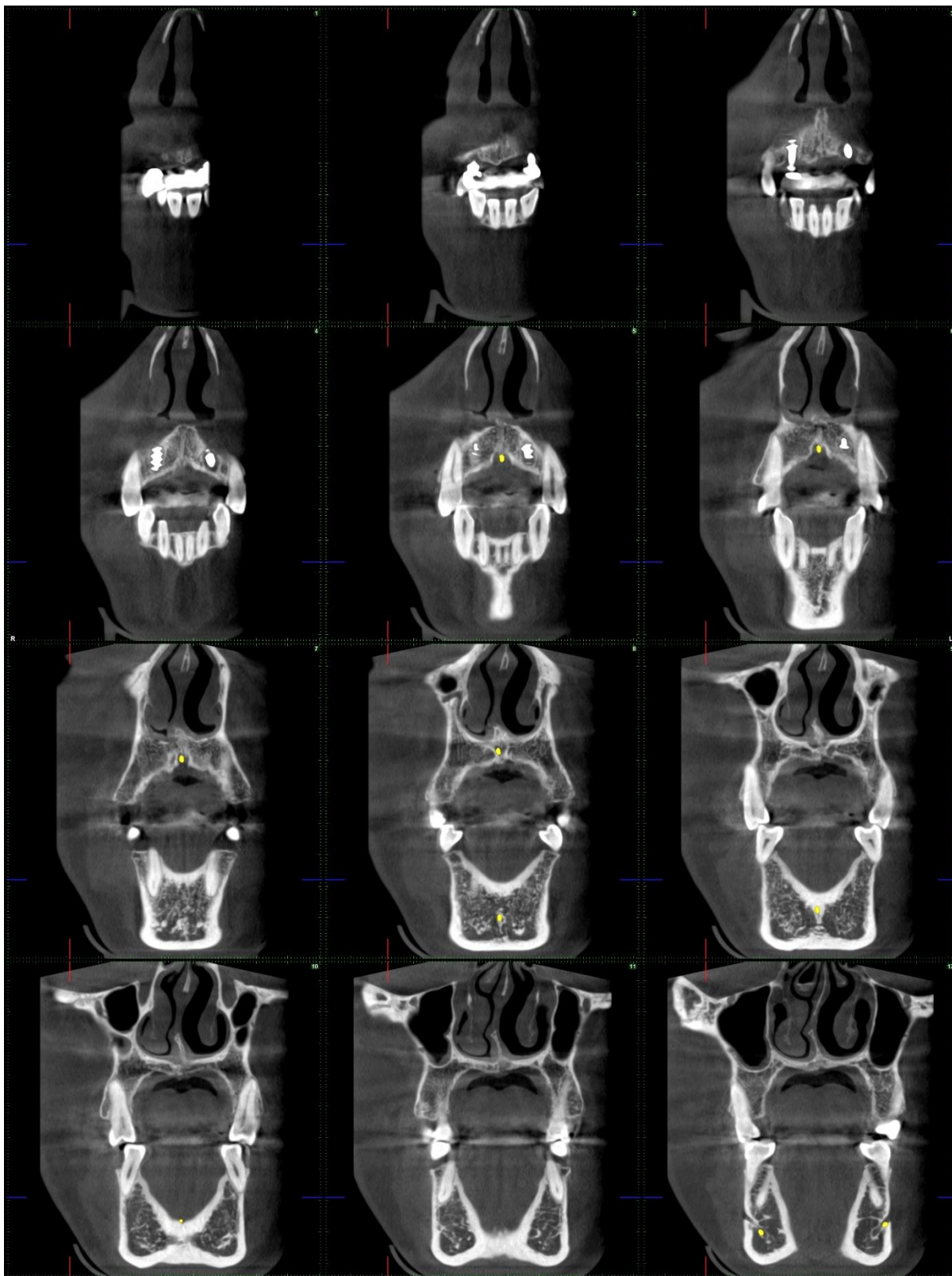
C SCANS

2D & 3D Digital Imaging
state of the art CBCT scan centre



CBCT REPORT

Coronal 2mm sections (Anterior to posterior)



C Scans

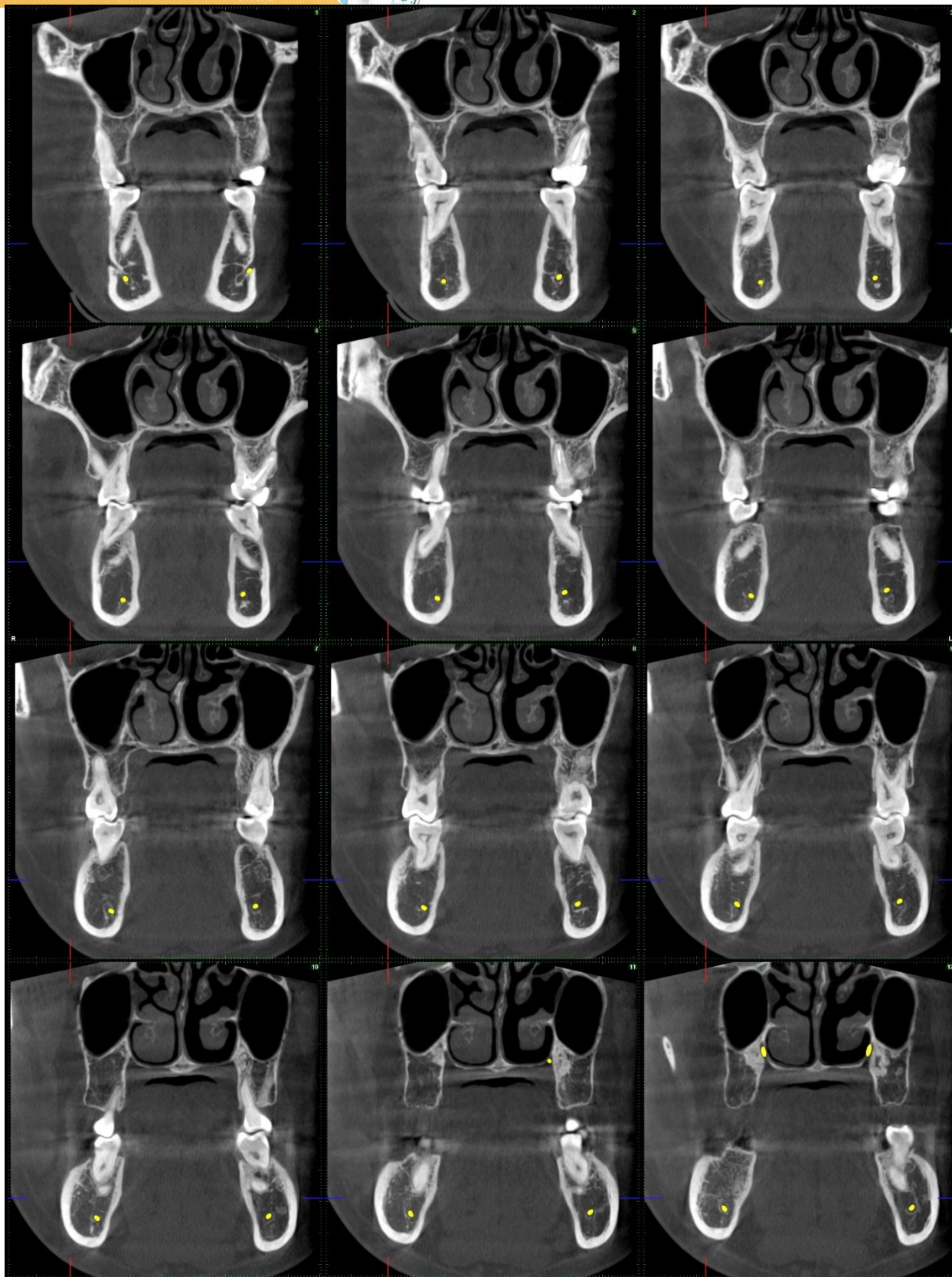


C SCANS

2D & 3D Digital Imaging
state of the art CBCT scan centre



CBCT REPORT



C Scans

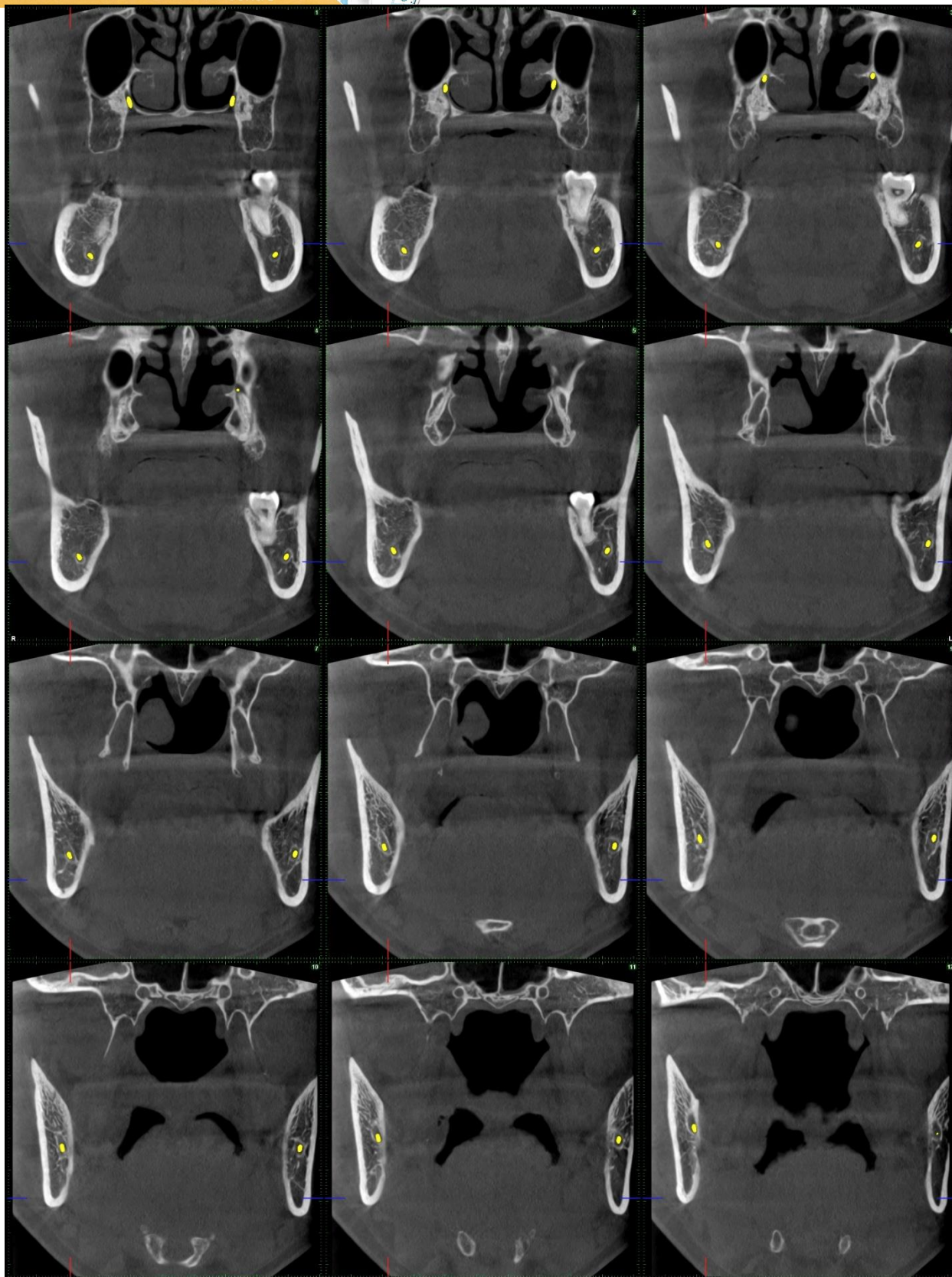


C SCANS

2D & 3D Digital Imaging
state of the art CBCT scan centre



CBCT REPORT



C Scans



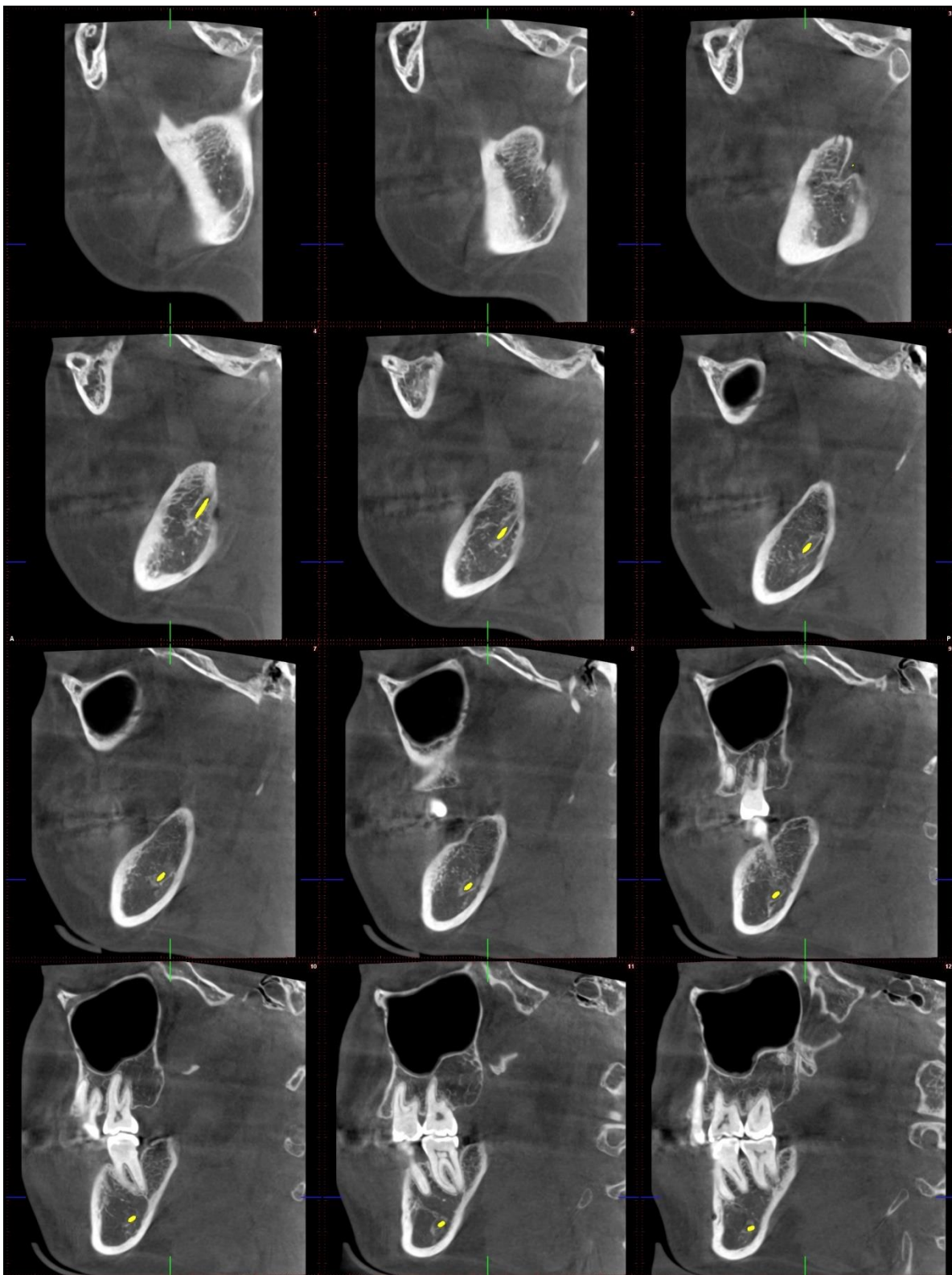
C SCANS

2D & 3D Digital Imaging
state of the art CBCT scan centre



CBCT REPORT

Sagittal 2mm sections (Right to left)



C Scans

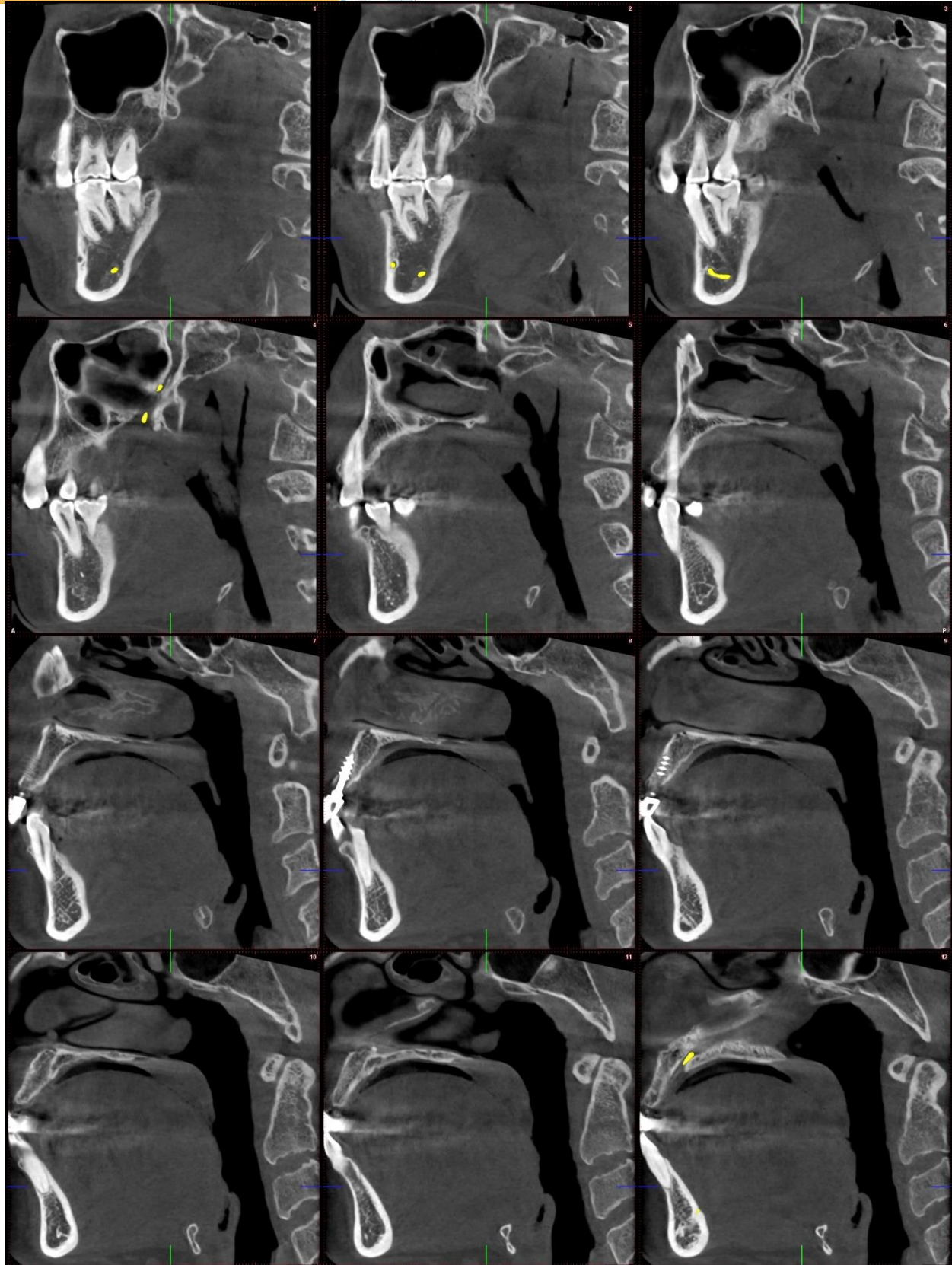


C SCANS

2D & 3D Digital Imaging
state of the art CBCT scan centre



CBCT REPORT



C Scans

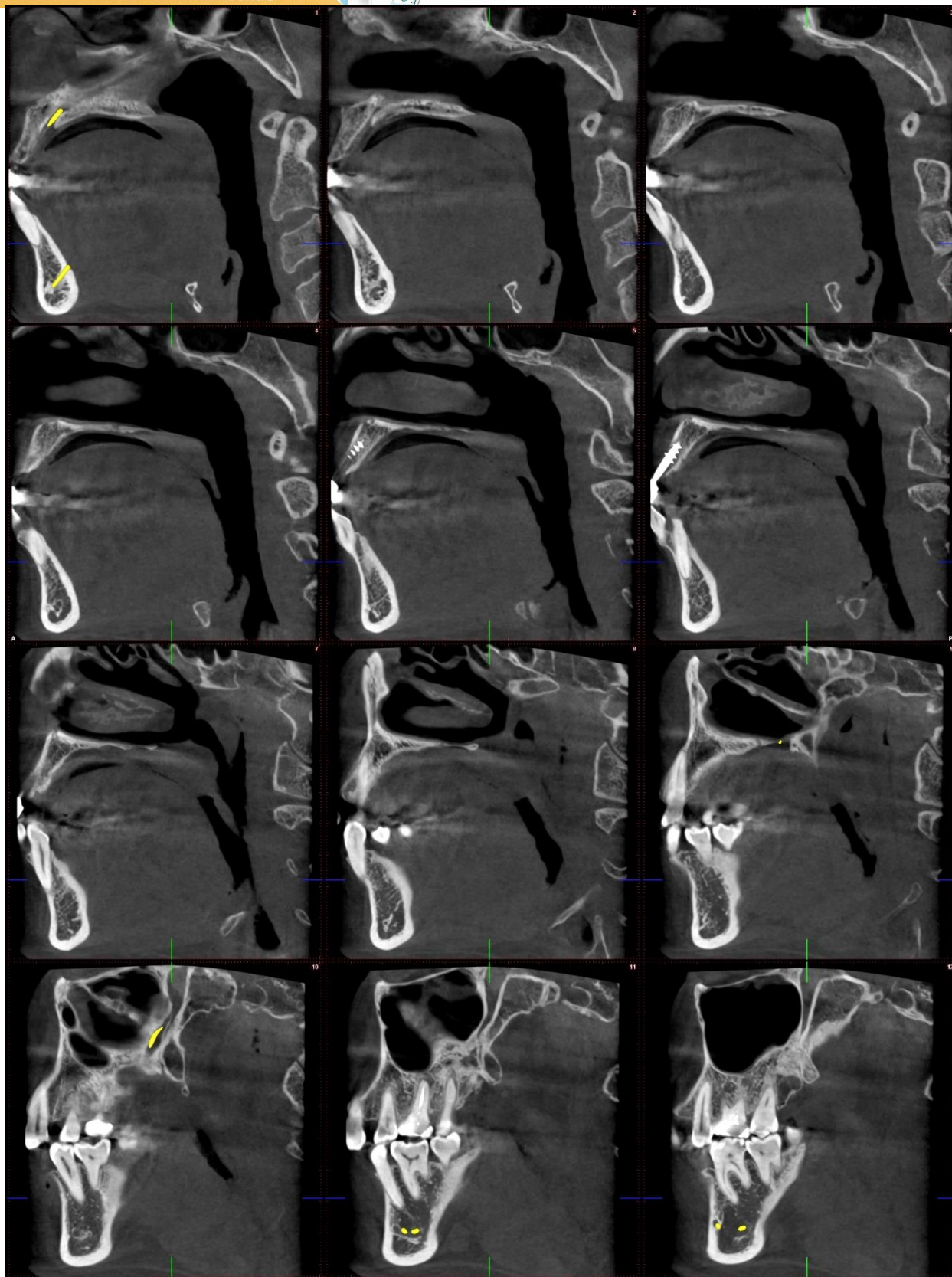


C SCANS

2D & 3D Digital Imaging
state of the art CBCT scan centre



CBCT REPORT



C Scans

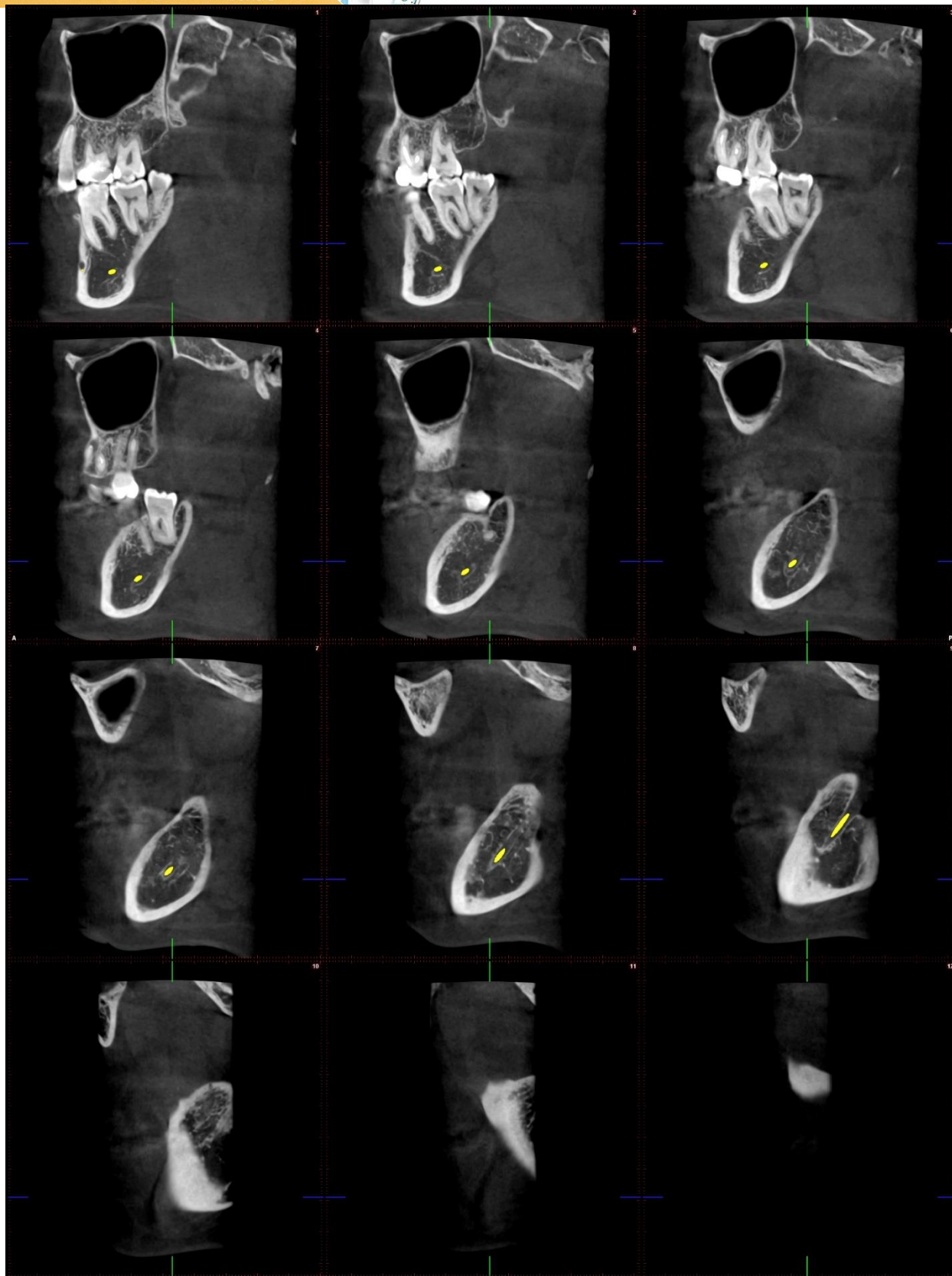


C SCANS

2D & 3D Digital Imaging
state of the art CBCT scan centre



CBCT REPORT



C Scans