

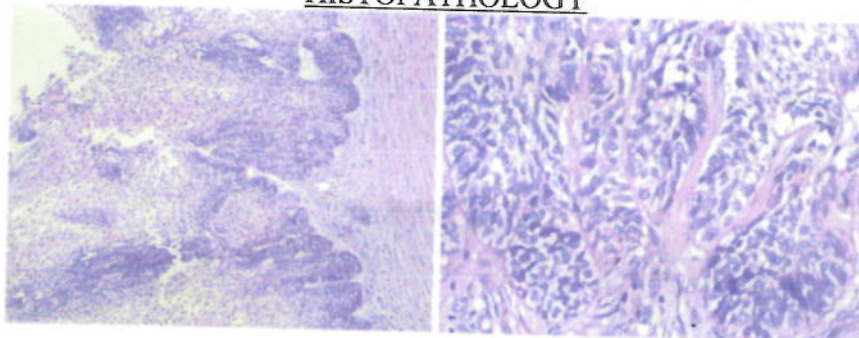


BIOPSY NUMBER: -
HP/ 6974 /24

PATIENT'S NAME : MR.KIRTHAN GOPAL AMIN
AGE : 35 YEARS
SEX : MALE
DATE & TIME OF RECEIPT: 15 /10 /2024

HOSP NO : 339074
WARD : 4D
DOCTOR/UNIT : Dr. Rithesh K B
DATE & TIME OF DISPATCH: 18 /10 /2024

HISTOPATHOLOGY



NATURE OF SPECIMEN: - EXCISION BIOPSY

GROSS FEATURES: - Received 2 bottles
Bottle 1 labelled as: Cystic lesion
Received a cut open fragmented cystectomy specimen altogether measuring 2.5x2x1cm
Outer surface: Cystic
Cut surface: Papillary projections noted, mucoid material present
Representative sections given in 2 blocks: A, B

Bottle 2 labelled as: Extracted teeth
Received 3 tooth largest measuring 2x0.5x0.5cm, 2nd largest measuring 1.5x1x0.6cm, smallest measuring 1.4x0.4x0.4cm, and a soft tissue measuring 2x1.5x0.5cm
Soft tissue all embedded in 1 block: C

MICROSCOPY: - A,B: Sections show well encapsulated tumor with central cystic area lined by tumor cells arranged in follicular pattern and plexiform pattern with peripheral palisading and reverse polarity of the nuclei. Stroma is edematous and show myxoid changes punctuated by blood vessels. Focal areas of squamous metaplasia noted. Tumor capsule shows plasma cells and eosinophilic infiltrate along with areas of hemorrhage

C: Section studied show bony trabeculae with underlying stroma and odontogenic epithelium with congested blood vessels.
Resected margin- Margins free from tumor.

IMPRESSION:- Excision biopsy : Plexiform Ameloblastoma

Signature:

Signature:

Grossing done by: Dr. Sandhya.I

Microscopy reported by: Dr. Sandhya. I

Note:

1. Correct identification of specimen by name of patient, age, sex, ward no, unit should be written on histopathology form and specimen by clinicians.
2. Specimens will be preserved for 1 month only.
3. For issue of histopathology slides, blocks or specimens, correct histopathology no should be given on requisition form.