



Written Consent

Date: 20/12/24

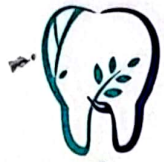①

A Patient by name Swathy Vachakkara Age: 37 years came to the clinic with the chief complaint of sensitivity in her lower back tooth region since 3 weeks which aggravates with cold beverages. On clinical oral examination it was found the patient had a FPD (fixed partial denture) bridge from tooth #18 to tooth #20. On radiographic examination it was found that tooth #18 had deep proximal caries (distally) and subgingivally, and radiolucency was seen approaching pulp chamber and RCT would be needed.

Therefore if RCT has to be done, the FPD bridge needs to be removed (sectioned) and the caries needs to be excavated and RCT needs to be initiated.

The patient has been informed regarding the same and she has given her consent for removal of the bridge to start the RCT (root canal treatment). The FPD (bridge) was done at her home country, and the patient will later replace the FPD (bridge) back in her home country.

Swathy
20/12/2024



DENTISTREE
DENTAL CLINIC

+971 4 252 9935 / 056 60 84 766

Shop 3, Wasl Port Views 8,

Next to Hyatt Place, Al Mina Road,
Jumeirah 1, Dubai.

info@dentistree.ae


After the removal (sectioning) of the bridge (CFPD),
the condition of the tooth will be evaluated,
if the tooth is restorable / has good prognosis
RCT will be done. Or else the tooth will
need to be removed (extracted).


Pt has given the consent for the same and
everything has been explained to the patient.

Swath
20/12/24



Dr. Reshma Faras


20/12/24.

 **Dr. Reshma Faras**
Specialist Endodontics
DENTISTREE DHA-61616991-001
DENTISTREE DENTAL CLINIC