



DEPARTMENT OF ORAL PATHOLOGY AND MICROBIOLOGY

AJ INSTITUTE OF DENTAL SCIENCES MANGALORE- 575004

[oralpathologydept@gmail.com](mailto:oralpathologydept@gmail.com)

**HISTOPATHOLOGY REPORT**

**Patient Details:**

Name: Kirthan Gopal Amin

OPD No: PVT

Age: 35 yrs

Biopsy No: 121/24

Sex: Male

Biopsy Received Date: 15-10-2024

Referred by: Dr. Rithesh K B

Date of Report: 21-10-2024

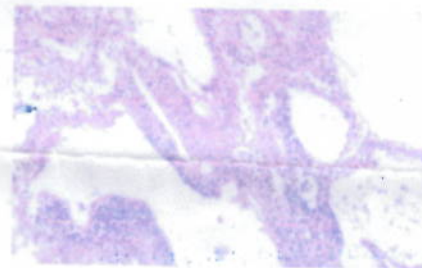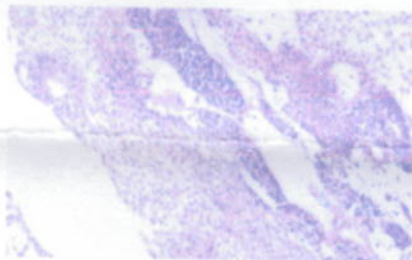
**Macroscopic Appearance:**

Received three pieces of soft tissue, grayish- white in color, firm in consistency, measuring 2.0x 1.0 x 0.2, cm in dimension, all embedded.

**Microscopic Features:**

The given H&E stained section shows a proliferating odontogenic epithelium in plexiform strands with peripheral tall columnar ameloblast like cells and central stellate reticulum like tissue. Microcystic spaces are seen. No keratinization or calcification noticed. Connective tissue is dense and fibrosed with normal cellularity.

**Impression: Plexiform Ameloblastoma**



Signature of Histopathologist

Dr. Nitin Gonsalves